

# A Retrospective Study of Caesarean Myomectomy in Modern Obstetrics

SAMBEDNA<sup>1</sup>, AMIT KUMAR<sup>2</sup>

## ABSTRACT

**Introduction:** Myomectomy during caesarean section was previously considered a relative contraindication with high complication rate. Now-a-days more number of caesarean myomectomies is being conducted as it avoids multiple surgeries and is considered safe.

**Aim:** To study and analyse the safety of Caesarean Myomectomy (CM) in the background of existing complications like intra-operative excessive bleeding and extended hospital stay.

**Materials and Methods:** All patients who underwent myomectomy during caesarean section in the tertiary care teaching hospital, during October 2017 to October 2018 were included in the study. Parameters like age, parity, gestational age, number of prior surgeries, size, number, type and location of

myomas were noted from outpatient and inpatients records. The ethical committee approved the study. It was a retrospectively designed descriptive study, so no specific test were applied. Percentages and standard deviation was calculated using SPSS 16.0 software.

**Results:** Common co-morbidities were Gestational Diabetes Mellitus (GDM) (20%) and hypothyroidism (40%). Mean size of myomas was 5.33 cm ( $\pm 2.08$ ) and number varied from one to four. The most common location was posterior surface of uterus and common type was subserous which comprised 10 of total myomas.

**Conclusion:** This study concludes that CM is a safe procedure from experienced hand (gynaecologists who have performed surgeries with minimum experience of 10 years).

**Keywords:** Caesarean delivery, Leiomyoma excision, Myoma uterus

## INTRODUCTION

Leiomyomata (fibroids) are the benign smooth muscle cell tumours of the uterus and female pelvis [1]. Uterine fibroids or myoma affects a large number of women during the reproductive age and leads to significant morbidity [2-5]. In modern obstetrics, the management of myoma during caesarean section is still a controversial issue [6,7].

The highest reported incidence is 10.7% [3]. The higher incidence during reproductive period is due to an influence of higher oestrogen level. Late age of conception partly explains the high incidence during pregnancy. In modern obstetrics various emerging literature supports myoma excision along with caesarean section with acceptable results [3,4].

Although technique for CM is same as intracapsular myomectomy but with newer caesarean endometrial myomectomy has advantage of less blood loss and less adhesion postoperatively [6]. This study aimed to retrospectively analyse the safety and feasibility of CM.

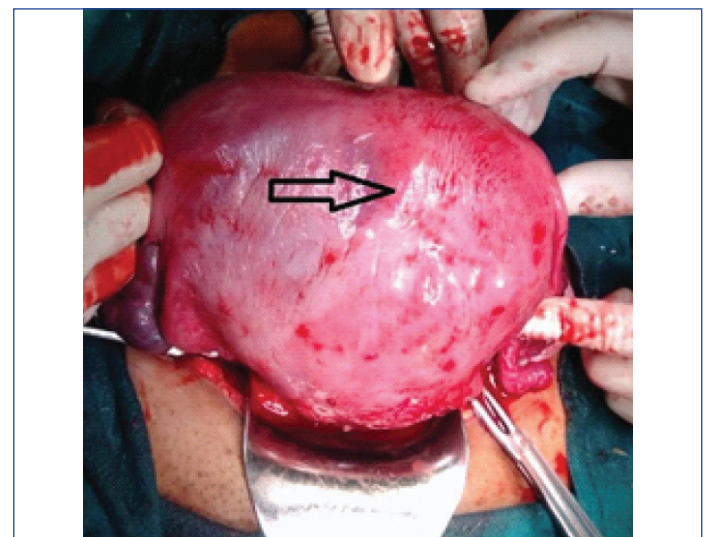
## MATERIALS AND METHODS

The present study was a retrospective analysis of all pregnant patients with myoma that underwent caesarean section with concomitant myomectomy. All the patients who had pregnancy with myomas were counseled during 3<sup>rd</sup> trimester regarding the need for myomectomy and consent was taken for the procedure. The data was collected from inpatient and outpatient records during October 2017 to October 2018 in North Delhi Medical College at Department of Obstetrics and Gynaecology. Permission from the hospital administration was obtained vide letter no. 10970/HRH/2017.

Data on the maternal age, parity, any prior surgery, gestational age at the time of caesarean section and indication for caesarean section were recorded. Indication for myomectomy, size, number, location and

variety of myoma were noted. Operative findings parameters like the number of incisions and the presence of adhesions were observed. The total duration of surgery was taken as the time from the initial skin incision to closure. Blood transfusion was given if fall of haemoglobin was more than 3 gm/dL postoperatively. Complications such as pyrexia ( $> 38^{\circ}$  C) and any wound infection were analysed. Follow-up data for two postoperative weeks were collected from outpatient records.

CM was done before delivery of foetus, if fibroids were located in lower segment of uterus [Table/Fig-1]. Single incision was made in most of the cases but in few cases where multiple myomas were present, more than one incision was required. The defect in the myometrium was closed. High-dose oxytocin infusion was continued with ringer lactate till 24 hours to prevent bleeding.



**[Table/Fig-1]:** Intraoperative picture of uterus with intramural myoma (arrow).

As this was a descriptive study various maternal demographics were analysed and percentages and standard deviation were calculated.

## STATISTICAL ANALYSIS

MS excel was used to calculate Mean and Standard deviation.

## RESULTS

Twenty patients with myomas ranging from 1 to 4 (mean 1) underwent caesarean section with concomitant myomectomy; with mean age of 30 years. Majority of the patients were nulliparous (60%). Common co-morbidities were GDM (20%) and hypothyroidism (40%). Fifty percent of surgeries were elective operations. The details of various preoperative characteristics are shown in [Table/Fig-2]. No patient warranted blood transfusion in the postoperative period.

Variables	Variable Value (mean±SD)
Age (in years)	30.84±3.83
<b>Parity</b>	<b>N (%)</b>
(a) Nulliparity	12 (60%)
(b) Multiparity	8 (40%)
Gestational Age (weeks)	37.3±1.08
<b>Number of prior surgeries</b>	<b>N (%)</b>
Nil	11 (55%)
LSCS	6 (30%)
Myomectomy	3 (15%)
<b>Co-morbidities</b>	<b>N (%)</b>
Diabetes Mellitus	4 (20%)
Hypothyroidism	8 (40%)
No co-morbidities	8 (40%)

**[Table/Fig-2]:** Demographic and preoperative characteristic of patients (n= 20). SD standard deviation, LSCS lower segment cesarean section

Majority of patients (16 of 24) got discharged on fourth postoperative day. There were no incidences of postpartum pyrexia or infection.

Many of the myomas which were anatomically at different walls of the uterus could not be differentiated as separate lesions as they overlapped, particularly in cases of intramural myomas intraoperatively [Table/Fig-3].

Variable	Value (mean±SD)
Size of myoma (cm)	5.33±2.08
Number of myoma (mean and range)	(1-4)
<b>Location of tumour*</b>	<b>N (%)</b>
(a) Posterior wall	6 (21.4%)
(b) Anterior wall	5 (17.8%)
(c) Right lateral wall	5 (17.8%)
(d) Fundus	4 (14.2%)
(e) Left lateral wall	4 (14.2%)
(f) Lower uterine segment	4 (14.2%)
<b>Type of Myoma</b>	<b>N (%)</b>
(a) Subserous	10 (50%)
(b) Intramural	8 (40%)
(c) Submucosal	2 (10%)
Operative time (minutes)	70±30.0
Blood loss (mL)	750±385
Hospital stay (days)	5±1.5

**[Table/Fig-3]:** Intraoperative variables (n=20). SD: Standard deviation; \*some patients also had multiple myomas

## DISCUSSION

CM has not been done on routine basis due to the risk of uncontrolled haemorrhage and the possibility of caesarean hysterectomy [7].

If CM is not performed, patient might need another surgery to remove it which amounts to risk of two operations, two anaesthetic exposures and increased cost and there is also an enhanced risk of complications caused by myoma in a subsequent pregnancy.

Most studies have shown myomas to be more common in nulliparous women [8].

In this study also there was a higher incidence of myomas among nulliparous women (60%). Nulliparous women had higher incidence of leiomyoma due to hormonal changes and reduced sensitivity of leiomyoma to oestrogen receptor. Similar to many other studies, the average gestational age at the time of caesarean section was 37 to 38 weeks in this study [7,9,10,11].

Myoma may cause preterm labour as pregnancy advances due to decreased distensibility of uterine myometrium [12]. Patients with previous myomectomy have more chance of complication, so it should be avoided in present pregnancy [13].

If the fibroid was situated in the incision site, then myomectomy was followed by caesarean section. Three cases of LUS fibroids which were less than 5 cm underwent myomectomy first followed by the delivery of the foetus. The fourth case underwent delivery first followed by CM as the myoma size was more than 5 cm. All fibroids present in the LUS were removed through the same caesarean incision. Many other surgeons have also practiced and recommended that myomectomy should be done first, if the myoma is located at LUS [14,15].

Three of the patients had undergone myomectomy previously in the nonpregnant state. One of the women had undergone myomectomy twice before becoming pregnant; this confirms the well-established fact that fibroids are recurrent [16]. Among the study group, the patients who had undergone previous myomectomies had a high incidence of intraoperative adhesions as expected. There were more posterior wall fibroids than anterior.

Removal of myoma in fundal and cornual region should be avoided due to risk of excessive bleeding and possible obstruction of fallopian tubes [17,18], but in this study, myomectomy was done regardless of the location of the myomas. Removal of submucosal fibroids during caesarean section involves resection of the full thickness of myometrium and hence is avoided. The reduced contractility might lead to increased haemorrhage [19]. Whenever possible, a minimal number of incisions were made and adjacent myoma was removed through the same incision. This was possible in 15 of the 20 patients. This was done to minimise blood loss and adhesions and improve future reproductive outcome. While the operating time was more or less uniform in most of the cases to be approximately 70 minutes, two of the cases exceeded the average operating time and it took almost 100 minutes to remove the multiple fibroids. The increased operating time could be explained by multiple myomas needing more than a single incision for appropriate removal. Various other studies have also observed more than average operating time in cases of multiple fibroids [20].

Risk of haemorrhage and the need for the hysterectomy makes CM an uncommon procedure [18]. Specific haemostatic techniques have been advocated by various authors [21,22], but tranexamic acid infusion, vasopressin instillation, uterine artery electrocautery and high-dose oxytocin were used in the study.

There was no increased postoperative morbidity in any of the patients who underwent CM. Kwon DH et al., also concluded that there was no significant difference in hospital stay based on size of the myoma [11].

The author would like to emphasise that routine myomectomy during caesarean section is not advisable and the authors also did not follow this in the current study. A recent review on this topic [23] has recommended the standardisation of practices for CM in view of feasibility, safety and surgeon's expertise.

## Limitation(s)

The study was retrospective in nature, had a limited sample size and lacked a long term follow up. Thus, external validation is recommended.

## CONCLUSION(S)

Overall, this study has shown CM to be a safe and feasible surgery from experienced hands in well-selected patients in a tertiary care centre. Surgeon should not abandon this procedure due to the risk of uterine atony and excessive bleeding. Hospital stay also remains unchanged. The future reproductive outcome and related morbidity should be addressed with larger prospective studies and with more robust data.

## REFERENCES

- [1] Baird DD, Dunson DB, Hill MC, Cousins D, Schectman JM. High cumulative incidence of uterine leiomyoma in black and white women: Ultrasound evidence. *Am J Obstet Gynecol.* 2003;188(1):100-07. doi:10.1067/mob.2003.99
- [2] Laughlin SK, Baird DD, Savitz DA, Herring AH, Hartmann KE. Prevalence of uterine leiomyomas in the first trimester of pregnancy: An ultrasound-screening study. *Obstet Gynecol.* 2009;113(3):630-35. doi:10.1097/AOG.0b013e318197bbaf.
- [3] Tian J, Hu W. Cervical leiomyomas in pregnancy: Report of 17 cases. *Aust N Z J Obstet Gynaecol.* 2012;52(3):258-61. <https://doi.org/10.1111/j.1479-828X.2012.01414.x>.
- [4] Tokgöz C, Hatirnaz Ş, Güler O. Pros and cons of myomectomy during cesarean section. *Caesarean Section.* 2018.
- [5] Sparic R, Kadija S, Stefanovic A, SpremovicRadjenovic S, LikicLadjevic I, Popovic J, et al. Cesarean myomectomy in modern obstetrics: More light and fewer shadows. *Journal of Obstetrics and Gynaecology Research.* 2017;43(5):798-804.
- [6] Hatirnaz Ş, Güler O, Başbuğ A, Çetinkaya M, Kanat-Pektaş M, Bakay K, et al. A Comparative multicentric study on serosal and endometrial myomectomy during cesarean section: Surgical outcomes. *Journal of Investigative Surgery.* 2020;33:1-8.
- [7] Incebiyik A, Hilali N, Camuzcuoglu A, Vural M, Camuzcuoglu H. Myomectomy during caesarean: A retrospective evaluation of 16 cases. *Archives of Gynecology and Obstetrics.* 2013;289(3):569-73.
- [8] Sparic R, Mirkovic L, Malvasi A, Tinelli A. Epidemiology of uterine myomas: A review. *Int J Fertil Steril.* 2016;9(4):424-35.
- [9] Kanthi JM, Sumathy S, Sreedhar S, Rajammal B, Usha MG, Sheejamol VS. Comparative study of cesarean myomectomy with abdominal myomectomy in terms of blood loss in single fibroid. *J Obstet Gynaecol India.* 2016;66(4):287-291. doi:10.1007/s13224-015-0685-x
- [10] Wise LA, Palmer JR, Harlow BL, Spiegelman D, Stewart EA, Campbell LLA et al. Reproductive factors, hormonal contraception, and risk of uterine leiomyomata in African-American women: A prospective study. *Am J Epidemiol.* 2004;159(2):113-23.
- [11] Kwon DH, Song JE, Yoon KR, Lee KY. The safety of cesarean myomectomy in women with large myomas. *Obstet Gynecol Sci.* 2014;57(5):367. <https://doi.org/10.5468/ogs.2014.57.5.367>.
- [12] Chen Y-H, Lin H-C, Chen S-F, Lin H-C. Increased risk of preterm births among women with uterine leiomyoma: A nationwide population-Based study. *Hum Reprod.* 2009;24(12):3049-56.
- [13] Sparic R, Berisavac M, Buzadzić S, Mirkovic L. Complications during cesarean delivery in a patient with two previous myomectomies. *Acta Chirugosl.* 2013;60(1):99-100.
- [14] Yellamareddygar S, Chakrabarti M, Ravuri S, Ahluwalia A. Leaving fibroids at caesarean section, is it safe? *Gynecol Surg.* 2010;7(2):173-75. <https://doi.org/10.1007/s10397-008-0441-7>.
- [15] Mahendru R, Sekhon P, Gaba G, Yadav S. At times, myomectomy is mandatory to effect delivery. *Ann Surg Innov Res.* 2011;5(1):9.
- [16] Ande ABA, Ehigiegba AE, Umeora OJU. Repeat myomectomy at caesarean section. *Arch Gynecol Obstet.* 2004;270(4):296-98.
- [17] Celal K, Hülya Ç. The evaluation of myomectomies performed during cesarean section in our clinic. *Niger Med J.* 2011;52(3):186.
- [18] Song D, Zhang W, Chames MC, Guo J. Myomectomy during cesarean delivery. *Int J Gynecol Obstet.* 2013;121(3):208-13. <https://doi.org/10.1016/j.ijgo.2013.01.021>.
- [19] Gbadebo AA, Charles AA, Austin O. Myomectomy at caesarean Section: Descriptive study of clinical outcome in a tropical setting. *J Ayub Med Coll Abbottabad.* 2009;21(4):7-9.
- [20] Ramesh Kumar R, Patil M, Sa S. The utility of caesarean myomectomy as a safe procedure: A retrospective analysis of 21 cases with review of literature. *J Clin Diagn Res.* 2014;8(9):OC05-OC08.
- [21] Shavell VI, Thakur M, Sawant A, Kruger ML, Jones TB, Singh M, et al. Adverse obstetric outcomes associated with sonographically identified large uterine fibroids. *Fertil Steril.* 2012;97(1):107-10.
- [22] Lee JH, Cho DH. Myomectomy using purse-string suture during cesarean section. *Arch Gynecol Obstet.* 2011;283(S1):35-37.
- [23] Chauhan AR. Cesarean myomectomy: Necessity or opportunity? *J Obstet Gynecol India.* 2018;68(6):432-36. <https://doi.org/10.1007/S13224-018-1114-8>.

### PARTICULARS OF CONTRIBUTORS:

1. Senior Resident, Department of Obstetrics and Gynecology, Hindu Rao Hospital, New Delhi, India.
2. Senior Resident, Department of Paediatric Surgery, Lady Hardinge Medical College, New Delhi, India.

### NAME, ADDRESS, E-MAIL ID OF THE CORRESPONDING AUTHOR:

Dr. Amit Kumar,  
Senior Resident, Department of Paediatric Surgery, Lady Hardinge Medical College, New Delhi, India.  
E-mail: amitsandilyaigims@gmail.com

### PLAGIARISM CHECKING METHODS: [Jain H et al.]

- Plagiarism X-checker: Mar 07, 2020
- Manual Googling: Apr 29, 2020
- iThenticate Software: Jun 13, 2020 (22%)

### ETYMOLOGY: Author Origin

### AUTHOR DECLARATION:

- Financial or Other Competing Interests: None
- Was Ethics Committee Approval obtained for this study? Yes
- Was informed consent obtained from the subjects involved in the study? Yes
- For any images presented appropriate consent has been obtained from the subjects. Yes

Date of Submission: **Feb 29, 2020**  
Date of Peer Review: **Mar 27, 2020**  
Date of Acceptance: **May 05, 2020**  
Date of Publishing: **Jul 01, 2020**